
ORIGINAL ARTICLE

A STUDY OF RETROPERITONEOSCOPIC PYELOLITHOTOMY WITH REFERENCE TO TYPE OF RENAL PELVIS-INTRARENAL AND EXTRARENAL

Gaurav Agrawal¹, Arvind Ghanghoria², Vaibhav Shrivastava³, Rajkumar Mathur⁴, Rupali Gupta⁵

HOW TO CITE THIS ARTICLE:

Gaurav Agrawal, Arvind Ghanghoria, Vaibhav Shrivastava, Rajkumar Mathur, Rupali Gupta. "A Study of Retroperitoneoscopic Pyelolithotomy with Reference to Type of Renal Pelvis-Intrarenal and Extrarenal". Journal of Evolution of Medical and Dental Sciences 2014; Vol. 3, Issue 55, October 23; Page: 12544-12552, DOI: 10.14260/jemds/2014/3663

ABSTRACT: OBJECTIVES: We report our experience with retroperitoneoscopic pyelolithotomy for renal pelvis stone disease (>1.5 cm) and comparisons were made with reference to type of renal pelvis, intrarenal or extrarenal. **MATERIAL AND METHODS:** Sixty patients underwent retroperitoneoscopic pyelolithotomy for large renal pelvis stone disease (>1.5 cm) in our hospital between 2008 and 2012. The patients in both the groups (Intrarenal or Extrarenal) were assessed preoperatively and intra operatively. Variables such as operative time, need for DJ stent placement either pre op/intra op / post op, drain placement, drain removal, post op mean hospital stay were compared between the two groups. We excluded patients with history of renal surgery. **RESULTS:** Conversion was required in five cases (8.3%). None of the patients landed in significant medical post op complications. In total DJ stent was inserted in 26 patients (43.3%), pre operatively, in eight patients and intra-operatively, in 18 patients. No patient required post op D J stent placement. Average duration of surgery was 133.4 mins. Mean postoperative hospital stay was 4.44 days. (Ranged from 3-8 days). **CONCLUSION:** Retroperitoneoscopic Pyelolithotomy is the preferred treatment modality in patients in which open surgery is contemplated. We conclude that it is better to place DJ stent either pre op or intra op since it facilitates suturing of pelvis. Drain removal was done slightly earlier in patients with intrarenal pelvis group. There was no significant difference in post-operative mean hospital stay among both the group. Conversion rate was more with intrarenal pelvis.

KEYWORDS: Intrarenal, extrarenal, retroperitoneoscopy, pelvis stone.

INTRODUCTION: Renal pelvis stones were traditionally dealt with open pyelolithotomy. In the era of minimal invasive surgery laparoscopic pyelolithotomy, in maximum cases has replaced open surgery even in very large pelvic stones. Initially it was transperitoneal laparoscopy which was preferred since it enabled the surgeons to work in the more spacious and relatively familiar peritoneal cavity. Clayman et al did transperitoneal laparoscopic nephrectomy in 1991.^[1] Retroperitoneal laparoscopy was first attempted by Wittmoser in 1973 for lumbar sympathectomy after blunt dissection with a telescope and pneumatic dissection with Co2.^[2]

The first retroperitoneoscopic ureterolithotomy was performed by Wickham in 1979.^[3] Retroperitoneoscopy was pioneered by Gaur et al which unveiled its utility. He constructed a simple device consisting of a no 7 surgical glove mounted on a red rubber catheter and created the workspace of the retroperitoneal laparoscopy by inflating the glove to 110 mm Hg using a pneumatic pump and manometer.^[4] Gaur successfully used this approach for multiple retroperitoneal procedures including simple nephrectomy, renal biopsy, ureterolithotomy and pyelolithotomy.^[5]

ORIGINAL ARTICLE

As illustrated by Gaur retroperitoneal laparoscopy can be used for various procedures like pelvic lymphnode dissection, ureterolithotomy and pyelolithotomy.^[6,7,8] Disadvantages of the retroperitoneoscopy being longer operative duration, poor visualization secondary to inadequate insufflation of retroperitoneum and considerable experience and training needed. Renal pelvis can be intra renal or extra renal. Type of renal pelvis has a bearing on various variables viz operative duration, need for DJ Stent and drain insertion, drain removal. The goal of this study is to project the efficiency of reroperitoneoscopic pyelolithotomy in 60 patients with large renal pelvis stone and compare pre op, intra op and post op variables with reference to intra renal and extra renal pelvis.

MATERIALS AND METHOD: We studied 60 patients with renal pelvis stone disease those presented to our hospital. In our study, we included the patients with renal pelvis stone those who were refractory to ESWL. Also we included the patients who were not willing for open surgery. We excluded the patients with history of any urological surgery in the past.

Patients were investigated pre operatively for renal function test, urine routine microscopic examination, Ultra sonogram KUB or Intra venous pyelography or CT-IVU. Obese patients in whom difficulty in assessing retroperitoneal anatomy was anticipated and those with painful obstructive hydronephrosis were considered for pre-operative DJ stent insertion.

Patients were made to undergo pre anesthetic check-up. After obtaining anesthetic fitness for surgery, patient was posted for retroperitoneal laparoscopic pyelolithotomy. The patient is positioned supine and general anesthesia is given and a Foley's urinary catheter is inserted. Patient is placed in the lateral decubitus position. Retroperitoneum is accessed from the space between the 12th rib superiorly, the iliac crest inferiorly, the lateral border of the paraspinal muscles poster laterally and the posterior axillary line antero medially.

A minimal (1 cm) lumbotomy cutaneous incision is performed 1 cm sub-costally and in parallel with the 12th rib, on the lateral border of the paraspinal muscles that projects roughly onto the posterior axillary line. The surgeon pierces the muscles and fascia with a Kelly clamp or an artery forceps all the way to the retroperitoneal posterior para renal space. At this point there is no significant vessel involving risk of hemorrhage.^[9] This tunnel is dilated until an index finger can be inserted to push the peritoneum forward, thus creating a retroperitoneal cavity.

This space is located between the fascia transversalis and gerota's fascia. Care must be taken to digitally dissect in an anterior plane and in a near 180 degree angle so as not to traumatize the paraspinal muscles. We do not use balloon dissection technique in our institute as described by Gaur.^[4] The second trocar (10 mm) is placed (under digital control), 2 cm above the iliac crest and 2 cm anteriorly to level of the 1st trocar in order to allow good mobility of the instruments and prevent swording.

The 3rd trocar (5 mm) is placed under digital control, at the same level with the 2nd trocar but 4 cm anteriorly (roughly at the mid axillary line). This port is reserved for the 0 degree optics handled by the first assistant. Then a 10 mm (1st) trocar with a foam grip is introduced through the initial lumbotomy incision and the incision is closed with 2 stitches. Through this trocar the surgeon interchangeably uses the monopolar scissors, the bipolar grasping forceps, suction device, needle holder and various large caliber instruments, a 10 mm right angle dissector, clip appliers and a retrieval bag.

ORIGINAL ARTICLE

Insufflation is begun at the pressure of 12 mm Hg and the camera is introduced through the 10 mm middle port. Using the telescopic dissection with fenestrated grasper with or without the bipolar cautery the surgeon frees the anterior abdominal wall from the peritoneum or fatty tissues in order to introduce the second and third trocars under laparoscopic control at the anterior axillary line across the 2nd or 3rd port sites. These trocars are used by the 2nd assistant for aspiration and various graspers during surgery. Co2 insufflation itself helps in creating space in the retroperitoneum.

Hereafter the laparoscope is introduced through the 3rd port.

Psoas muscle is the most important anatomical landmark for retroperitoneoscopy. Other anatomical landmarks are the ureter, spermatic /ovarian vein, the vena cava and lower pole of the kidney. Renal fascia is opened longitudinally for the exposure of kidney. After dissection of the fascia mid and lower pole of kidney are identified, then identification of the renal pelvis and ureter is done. After identification of the renal pelvis, in a case of extrarenal pelvis, stone can be palpated with the grasper provided the stone is big.

Intrarenal pelvis poses significant difficulty and needs more expertise. Steps in the identification of intrarenal pelvis are same as that in open surgery. Good surgical experience of open pyelolithotomy makes the procedure simpler. In patients with intrarenal pelvis, subparenchymal (space of Gil-Vernet) dissection may be required for better exposure of the renal pelvis.^[10] Incision is made over the pelvis with the scissors. Stones are extracted with an endo bag or with a gloved finger bag if the stone is small.

In some cases we did intra operative D J stent insertion, so as to facilitate closure of pelvis and good healing, especially in cases of intrarenal pelvis where chances of stricture formation are high after watertight suturing. The pelvis is sutured at the end of the procedure with interrupted sutures. One drain is placed in the peri nephric space 20 or 24 Fr, introduced through camera port (posterior axillary line). We did drain insertion in all the operated patients. Fig II Giant renal calculus (8 cm) extracted from an extrarenal pelvis.

POST OP: In both the groups (Intrarenal and Extrarenal), Foleys catheter was removed on the 1st post op day. Drain removal was done when collection in the drain was less than 50 cc for the first 24 hrs. DJ stent removal (if inserted) is done after 4-6 weeks.

RESULTS: Mean age of the patients who underwent the procedure was 38.9 years. Patients were categorized based on type of calculus whether staghorn, solitary or multiple. Out of which 21 patients (35%) had staghorn calculus, 21 patients (35%) had solitary calculus and 18(30%) had multiple calculi. Out of all the patients operated 35 patients (58.3%) were found to be having extrarenal pelvis intra-operatively. Twenty five patients (41.6%) had intrarenal pelvis. Drain was placed in all patients. Double J stent insertion was done in total 26 patients (43.3%). Pre operatively DJ stent placement was done in eight patients (13.3%), out of those 8 patients, three patients (5%) had extrarenal pelvis and five patients (8.3%) had intrarenal pelvis.

Intra-operatively DJ stent was inserted in 18 pts. (30%), out of which six patients had extrarenal pelvis (10 %) and 12 patients had intrarenal pelvis (20%). No patient landed in post op urinoma formation? Mean duration of surgery was 133.4 mins (75-210 mins), extrarenal group 132.4 mins (75-210 mins) and intracranial group was 134.6 mins (90-190 mins). Drain removal was done on average 3.02 days (1-7 days).

ORIGINAL ARTICLE

Drain was kept for an average duration of 3.11 days in extrarenal group and 2.64 days for intrarenal group. Mean post-operative hospital stay was 4.43 days. Mean post op hospital stay was 4.42 days for extrarenal pelvis and it was 4.44 days for intrarenal pelvis. Conversion to open surgery was required in five cases (8.3%), in two patients due to large staghorn calculus which made the stone retrieval difficult, in one patient due to hemorrhage from renal parenchyma, one patient due to difficult renal anatomy and one patient developed subcutaneous surgical emphysema which made ventilation difficult.

Four patients (6.6 %) presented with minor surgical complications like wound infection. None of the patients landed in significant medical post op complications. Table 1 shows difference between extrarenal and intrarenal groups pre operatively. Table 2 showing Comparison between intrarenal and extrarenal pelvis: Intra op and Post op variables. Fig 1 Bar chart showing patients with DJ stent: Intra op/ Pre-operative in Intracranial and extrarenal group.

DISCUSSION: Renal calculus disease is the third most common urological condition afflicting the society after Urinary tract infection and benign prostate conditions. Factors to be considered while determining treatment modality is stone size, its location and composition of the stone. Laparoscopic management of urolithiasis was first demonstrated by Wickham.^[3] At present majority of the renal calculus can be dealt with SWL and PCNL, which are effective, least invasive and associated with less complication rates. Complications being various degrees of renal trauma and a higher incidence of renal stones.^[11] Open surgery is contemplated if the abovementioned measures fails.

In the era of minimal invasive surgery laparoscopy has rapidly replaced open surgery especially if a concomitant pyeloplasty is required. In our set up, which is a tertiary care Government hospital when we started our study the facilities to perform PCNL was not available. Therefore patients who were not willing for open surgery were resorted to laparoscopic pyelolithotomy. Most of the urological surgeries including pyelolithotomy are extraperitoneal. Laparoscopic pyelolithotomy in its earlier days was transperitoneal to start with, reason being better acquaintance of general surgeons with the peritoneal cavity, which is more spacious.^[12]

Laparoscopic transperitoneal pyelolithotomy trespasses the peritoneal cavity with increased risk of bowel injury which delays the post op recovery of the patient. Post op urinoma formation due to urinary leak adds to the concern. All these shortcoming led to the development of retroperitoneoscopic approach to renal pelvis. Retroperitoneal approach is not superior to transperitoneal approach in terms of visualization, access or dissection of the kidney.

Although Retroperitoneal cavity is smaller as compared to peritoneal cavity but retroperitoneoscopy confers distinct advantage due to its direct approach, enabling visualization of retroperitoneal structures and landmarks. Since the peritoneum is not opened, risk of post op adhesions and urinary peritonitis is minimized. Individual bowel loops need not be retracted only the peritoneal covering can be retracted. It would not be an exaggeration to say that retroperitoneoscopy or lumboscopy meet all the criterias of open renal surgery without transgressing the abdominal cavity.^[13,14,15,16,17]

Limitations of the retroperitoneal approach include the possible obliteration of this potential space by previous surgical procedures or inflammatory processes.

ORIGINAL ARTICLE

Patients with the history of previous renal surgery were excluded from our study. Retroperitoneoscopy has several limitations as well. Firstly, limited skin area makes port placement difficult.

Secondly, anatomical landmarks in retroperitoneum are relatively few as compared to peritoneum. Thirdly, in obese patients excessive fat may make visualization of retroperitoneal cavity difficult. Gaur was the first to develop retroperitoneoscopy and to carry out a nephrectomy by using balloon dissection for creating the working space. We found the single digital dissection sufficient for adequate exposure of the retroperitoneum. The peritoneum is separated from the abdominal wall by the index finger of the surgeon being introduced through the subcostal incision.

The first two trocars are placed under digital control. The wide longitudinal incision of the renal fascia performed at the beginning of the procedure helps to enlarge the working space. An important factor is the optimal exposure of the entire surgical field before starting dissection at the renal hilum. Recent studies confirm that the operative duration, blood loss and risk of complications decrease with the experience of the surgeon. In our study none of the patients needed blood transfusion. Conversion to open surgery need not signify complication.

In our study we did conversion in five patient's i.e., 8.3 %. In two patients due to large stag horn calculus which made the stone retrieval difficult, in one patient due to hemorrhage from renal parenchyma, in one patient due to difficult renal anatomy and in one patient due to subcutaneous surgical emphysema which led to difficulty in ventilation. The reason for subcutaneous surgical emphysema can be attributed to leakage of CO₂ from the port site. Kumar et al reported surgical emphysema in 5.3% patients undergoing various retroperitoneoscopic procedures.^[19]

To prevent such complications it is prudent to avoid creating any planes between skin, subcutaneous tissue and the muscle planes. Also a small incision is made in the thoracolumbar fascia. Port cannula should be fixed by placing purse string sutures with silk around all the layers of abdominal wall. Four patients (6.6 %) presented with minor surgical complications like wound infection.

None of the patients landed in significant medical post op complications. In retroperitoneoscopy it is rare to traumatize a vessel at the time of insertion of trocar. Indeed there are no important vessels being along the specific area of abdominal wall and the digitally guided insertion of trocars prevents any injury to large abdominal vessels.^[9]

The pelvis can be extra renal or intrarenal. An intrarenal pelvis can be defined as the one which is relatively inaccessible, embedded in the renal parenchyma and with a caliber barely larger than the ureter. Contrary to the intrarenal pelvis, an extrarenal pelvis is exposed outside the parenchyma and is easily reachable. The renal pelvis joins the ureter at the UPJ. Normal pelvis volume is 3-5 ml. A stone in a kidney with an extra renal pelvis is easier to remove than a stone in a kidney with an intrarenal pelvis.^[10]

Firstly visualization of an extra renal pelvis is simpler when compared to intrarenal variety. Dissection in extra renal variety is also simple, reason being presence of redundant pelvis. Dissection of an intrarenal pelvis is difficult because of its location within the renal sinus. Moreover, the pyelotomy incision tends to retract behind the renal substance making intracorporeal suturing more difficult. Insertion of Double J stent in renal pelvis is not a must for retroperitoneoscopic pyelolithotomy. D J insertion can be done either preoperatively, intra-operatively or post operatively.

ORIGINAL ARTICLE

When inserted preoperatively it reduced the difficulty during procedure especially in a case of intrarenal pelvis. Also it facilitates the urine flow. Among the shortcomings of pre-operative DJ stent insertion is the decompression of the PC system, thus altering the appearance of disease process. Intra-operatively DJ Stent insertion reduces the risk of stricture formation with watertight suturing specially in cases with intrarenal pelvis. Also it obviates the need for cystoscopy and position for insertion.

Disadvantage of intra op DJ stent insertion includes increased duration of surgery. We would also like to discuss the shortcomings of our study. Firstly, the sample size (n=60) is rather small and it is difficult to arrive at a conclusion based on the study. Secondly, the conversion rate is high (8.3%). Thirdly, many patients could have been a better candidate for PCNL especially the patients with large renal pelvic stone.

FOLLOW UP: All patients are on regular follow up. No stone related complications have been reported till date.

CONCLUSION: From our experience of 60 cases of retroperitoneal laparoscopic pyelolithotomy it can be concluded that in patients in whom open surgery is contemplated retroperitoneoscopic pyelolithotomy is the preferred treatment modality. In our study we compared preop/intraop/postop variables in patients having intrarenal and extra renal pelvis. We conclude that it is better to place DJ stent either pre op or intra op since it facilitates pelvic suturing and reduces risk of post op urinoma formation especially in patients with intrarenal pelvis where chances of stricture are high.

Drain removal was done slightly earlier in patients with intra renal pelvis. There was no significant difference in post-operative mean hospital stay among both the group of patients. Also it has been found that average duration of surgery was slightly more in intra renal pelvis group as compared to extrarenal group. Complication rates were nearly similar in both the groups. Conversion rate was more with intrarenal pelvis.

REFERENCES:

1. Clayman RV, Kavoussi LR, Soper NJ, Dierks SM, Meretyk S, Darcy MD, Roemer FD, Pingleton ED, Thomson PG, Long SR Laparoscopic Nephrectomy: Initial case report. J Urol.1991; 146: 272-278.
2. Wittmoser R Die Retroperitoneoskopie als neue Methode der lumbalen Sympathikotomie Fortschr Endoskopie 4: 219-1973.
3. Wickham JEA. The surgical treatment of urinary lithiasis. In: Wickham JEA (ed.). Urinary Calculus Disease. Churchill Livingstone, Edinburgh, 1979; 145-98.
4. Gaur D Laparoscopic operative retroperitoneoscopy: Use of a new device J Urol 1992; 148: 1137-1138.
5. Gaur DD, Agarwal DK, Purohit KC, Darshane AS. Retroperitoneal laparoscopic pyelolithotomy. J. Urol. 1994; 151: 927-9.
6. Kavoussi LR, Sosa E, Chandhoke P. Complications of laparoscopic pelvic lymph node dissection. J Urol.1993; 149: 322-325.
7. Master J E, Fraundorfer MR, Gilling PJ Extraperitoneal laparoscopic pelvic lymph node dissection using Gaur balloon technique.Br J Urol. 1994; 74: 128-129.
8. Munch LC, Delworth MG, Gill IS Retroperitoneal laparoscopic ureterolithotomy. J Endourol. 1993; 7: 137-138.

ORIGINAL ARTICLE

9. Hoznek A, Salomon L, Gettman M, Stolzenburg JU, Abbou CC Justification of extraperitoneal laparoscopic access for surgery of the upper urinary tract. *Current urology reports*. 2004; 5: 93-99.
10. Adel Al-Hunayan, 1 Hamdy Abdulhalim, 2 Ehab El-Bakry, 2 Majed Hassabo 2 and Elijah O Kehinde Laparoscopic pyelolithotomy: Is the retroperitoneal route a better approach? *International Journal of Urology* (2009) 16, 181-186.
11. Goel A, Hemal AK. Evaluation of role of retroperitoneoscopic pyelolithotomy and its comparison with percutaneous nephrolithotripsy. *Int. Urol. Nephrol.* 2003; 35: 73-6.
12. Chung HJ, Meng mv, Abraham HM, Stoller ML. Upper quadrant access for urologic laparoscopy. *Urology* 2000, 62: 1117-1119.
13. Gill IS, Dayman RV, Albala DM, Aso Y. Retroperitoneal and pelvic extraperitoneal laparoscopy: an international perspective *J Urology* 1998; 52: 566-571.
14. Gill IS, Kavoussi LR, Clayman RV, Ehrlich R, Evans R, Fuch SG, Gersham A, Hulbert JC, McDougass EM, Rosenthal T. Complications of laparoscopic nephrectomy in 185 patients a multi institutional review. *J Urol.* 1995; 154: 479-83.
15. Fahlenkamp D, Rassweiler J, Fornara P, Frede T, Loening SA. Complications of laparoscopic procedures in Urology. Experience with 2407 procedures at 4 German centres. *J Urol* 1999; 162: 765-768.
16. Rassweiler J, Frede T, Henkel TO, Stock C, Alken P Nephrectomy: A Comparative study between the transperitoneal and retroperitoneal laparoscopic versus the open approach. *Eur Urol.*1998; 33: 489-496.
17. Shivde Sr, Eden CG, Retroperitoneal laparoscopy. *BJU Int.*2000; 85: 777-779.
18. Dimitri L, Alexandre D L T, Guillaume P, Gregoire R, Laurence B, Andras H, Dimitri V, Claude A, Laurent S. Analysis of complications from 600 retroperitoneoscopic procedures of the upper urinary tract during the last 10 years. *World Journal of Urology* 2008; 26 (6): 523-30.
19. M Kumar, R Kumar, A K Hemal and N P Gupta, Complications of retroperitoneoscopic surgery at one Centre; *BJU International* (2001), 87, 607-612.

SL. NO.	FACTORS	EXTRARENAL PELVIS	INTRARENAL PELVIS
1	INTRAOP DJ STENT	6/35	12/25
2	DURATION	132.4 min	134.6 min
3	DRAIN PLACEMENT	ALL	ALL
4	TRANSFUSION	-	-
5	DRAIN REMOVAL (days)	3.11	2.64
6	POST OP MEAN HOSPITAL STAY	4.433 days	4.428 days
7	COMPLICATIONS	2 (WOUND INFECTION)	2 (WOUND INFECTION)
8	CONVERSION	1 (Sutaneous surgical emphysema)	4 (2 -difficult stone retrieval, 1 - excessive bleeding renal parenchyma,1-difficult renal anatomy)

Table 1: Showing Comparisions between intrarenal and extrarenal pelvis: Intra op and Post op variables

ORIGINAL ARTICLE

Sl. NO	FACTORS	EXTRARENAL PELVIS	INTRARENAL PELVIS
1	MEAN AGE	36.2 yrs	40.68 yrs
2	TYPE OF CALCULUS- SOLITARY/STAGHORN/MULTIPLE	SOLITARY-11/35 MULTIPLE-10/35 STAGHORN-14/35	SOLITARY-10/25 MULTIPLE-8/25 STAGHORN-7/25
3	MEAN SIZE	2.51 CMS	2.52 CMS
4	COEXISTING MORBIDITIES	4	3
5	PREOP DJ STENT	3/35	5/25

Table 2: Shows differences between extrarenal and intrarenal groups pre operatively

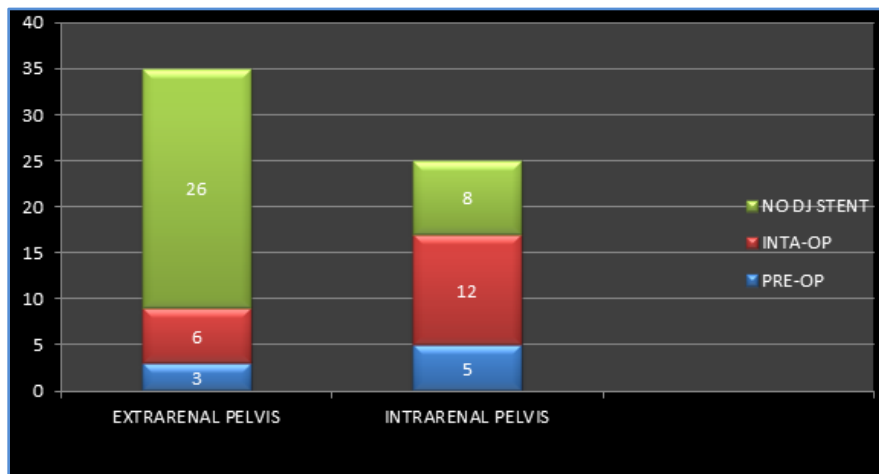


Fig. 1: Bar chart showing patients with DJ stent: Intra op/ Pre-operative in Intrarenal and extrarenal group

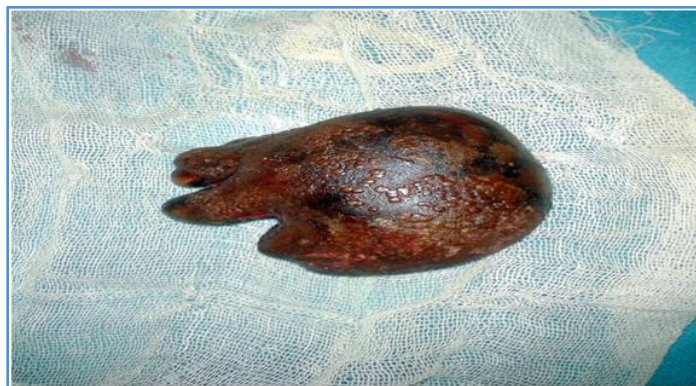

Fig. 2: Giant renal calculus (8 cm) extracted from an extrarenal pelvis

AUTHORS:

1. Gaurav Agrawal
2. Arvind Ghanghoria
3. Vaibhav Shrivastava
4. Rajkumar Mathur
5. Rupali Gupta

PARTICULARS OF CONTRIBUTORS:

1. Senior Resident, Department of Surgery, MGM Medical College & M. Y. Hospital, Indore, M. P.
2. Associate Professor, Department of Surgery, MGM Medical College & M. Y. Hospital, Indore, M.P.
3. Assistant Professor, Department of Surgery, MGM Medical College & M. Y. Hospital, Indore, M. P.

4. Professor & HOD, Department of Surgery, MGM Medical College & M. Y. Hospital, Indore, M. P.
5. Resident, Department of Radio-diagnosis, MGM Medical College & M. Y. Hospital, Indore, M. P.

NAME ADDRESS EMAIL ID OF THE CORRESPONDING AUTHOR:

Dr. Gaurav Agrawal,
S/o Dr. Sharad Chandra Agrawal,
28, Shashtri Nagar,
Khandwa, Madhya Pradesh.
Email: drgauravagrwal1985@gmail.com

Date of Submission: 08/10/2014.
Date of Peer Review: 09/10/2014.
Date of Acceptance: 17/10/2014.
Date of Publishing: 21/10/2014.